

Transient Blindness in a Patient with Severe Metformin-Associated Lactic Acidosis (MALA)

Jae Wan Jeon¹, Wonjung Choi¹, Hae Ri Kim¹, Young Rok Ham¹, Dae Eun Choi¹, Ki Ryang Na¹, Kang Wook Lee¹, Soo Ya Bae², Seong Hoon Kim³

¹Division of Nephrology, Department of Internal Medicine, Chungnam National University College of Medicine, Daejeon,

²Department of Internal Medicine, Busan Bumjin Hospital, Busan,

³Department of Internal Medicine, Asan Medical Center, University of Ulsan College of Medicine, Seoul, Korea

Received: May 1, 2019

Revised: May 12, 2019

Accepted: May 13, 2019

Corresponding Author: Jae Wan Jeon, MD, PhD

Division of Nephrology, College of Medicine,

Chungnam National University Hospital, 282,

Munhwa-ro, Jung-gu, Daejeon 35015, Korea

Tel: +82-42-280-7235

Fax: +82-42-280-8392

E-mail: jeonjwan@cnuh.co.kr

A 68-year-old man presented at the emergency room with sudden blindness. The day before, he had eaten sashimi and eel and drank alcohol for dinner. He experienced nausea, vomiting, and dizziness afterward. His medical history included hypertension and diabetes, and the latter was treated with metformin. Initial laboratory tests revealed severe metabolic acidosis (lactic acidosis). Massive hydration and intravenous sodium bicarbonate replacement therapies were initiated, but severe metabolic acidosis (lactic acidosis) did not resolve, in turn, leading to hemodialysis, which decreased metabolic acidosis. The patient's blindness improved, and his vision gradually recovered. As it is not easy to distinguish between blindness related to metformin-associated lactic acidosis (MALA) and blindness related to other causes, rapid correction of metabolic acidosis through hemodialysis might be helpful in differentiating this from of blindness from blindness related to other causes.

Key Words: Transient blindness, Metformin-associated lactic acidosis (MALA), Metabolic acidosis, Hemodialysis

This is an Open Access article distributed under the terms of the Creative Commons Attribution Non-Commercial License (<https://creativecommons.org/licenses/by-nc/4.0/>) which permits unrestricted non-commercial use, distribution, and reproduction in any medium, provided the original work is properly cited.

Introduction

Metformin is the most commonly used oral hypoglycemic agent in patients with diabetes. The frequently reported adverse effects of metformin are gastrointestinal side effects, including nausea, vomiting, and diarrhea¹. Lactic acidosis may occur as a serious adverse reaction to metformin and should be considered as a factor contributing to decreased renal function in some patients². The reported incidence of metformin-associated lactic acidosis (MALA) is 4.3 cases/100,000 patient-years, mostly in patients with predisposing factors³. In cases of lactic acidosis caused by metformin, the drug is stopped, and hemodialysis is performed when necessary⁴. We report a case of MALA that resulted in transient blindness.

Case Report

1. Patient information

A 68-year-old man with sudden blindness presented at our emergency room. The day before, he had eaten sashimi and eel, and drank alcohol for dinner. Afterward, he experienced nausea, vomiting, and dizziness. His medical history included diabetes and hypertension. His diabetes, diagnosed more than 20 years ago, was at the time treated with metformin 1,000 mg twice a day, glimepiride 2 mg once a day, and linagliptin 5 mg once a day. Concurrently, his hypertension was treated with telmisartan 80 mg/amlodipine 5 mg once a day.

2. Clinical findings

At the time of admission to the emergency room, the patient's blood pressure was 104/57 mmHg, heart rate 86 beats/min, body temperature 34.3°C, and the pulse oximeter reading was 98% on room air. The patient was alert and although the light reflex was intact, the patient reported seeing no light in either eye even when a pen-light was shone into the eyes. No other focal neurological deficits were observed.

3. Diagnostic assessment

Brain computed tomography (CT) and brain magnetic resonance imaging & angiography (MRI & MRA) were performed. Brain CT and MRI showed no acute lesions. No significant stenosis of the cerebral artery was seen on MRA.

The first venous blood gas analysis (VBGA) test at admission showed pH, 6.78; pCO₂, 26.7 mmHg; pO₂, 38 mmHg; bicarbonate, 4.0 mmol/L; and total CO₂ <5 mmol/L. The first arterial blood gas analysis (ABGA) test showed pH, 6.93; pCO₂, 16 mmHg; pO₂, 120 mmHg; bicarbonate, 3.4 mmol/L; total CO₂, 4 mmol/L; and SaO₂, 95%. The initial laboratory data revealed the following: white blood cell (WBC), 35,300/μL; hemoglobin (Hb), 15.0 g/dL; platelets, 284,000 K/μL; BUN, 36.8 mg/dL; creatinine, 2.31 mg/dL; sodium 141.1 mEq/L; potassium, 5.80 mEq/L; chloride, 99.2 mEq/L; total calcium, 9.9 mg/dL; phosphorus, 11.6 mg/dL. Lactic acid was measured as >11 mmol/L on admission. Urinalysis showed protein 2+, glucose -, and ketone 1+, and urine microscopy showed red blood cell (RBC) 3-5/HPF and WBC 6-10/HPF.

Massive hydration and intravenous sodium bicarbonate replacement were initiated for severe metabolic acidosis (lactic acidosis), but the metabolic acidosis did not change. Nevertheless, after three hours of hydration and sodium bicarbonate supplementation, while the metabolic acidosis remained unchanged, the patient's vision gradually recovered.

4. Follow up and outcomes

After 30 minutes of visual recovery, an ophthalmologic

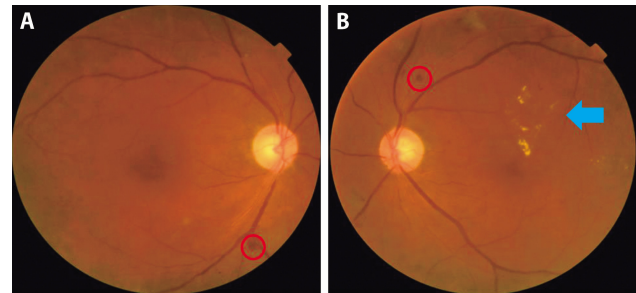


Fig. 1. Fundoscopic examination. (A) Right eye, a dot-like retinal hemorrhage was observed (red circle), (B) Left eye, a dot-like retinal hemorrhage (red circle) and hard exudate (arrow) were observed, showing severe non-proliferative diabetic retinopathy.

examination was performed. Diabetic retinopathy and cataract were found. No lesions that would cause blindness were identified (Fig. 1).

Although field of vision and visual acuity were restored, metabolic acidosis did not resolve completely (pH, 7.11; pCO₂, 18 mmHg; pO₂, 77 mmHg; bicarbonate, 5.7 mmol/L; total CO₂, 6 mmol/L; SaO₂, 93% on ABGA). Hemodialysis (HD) was performed once, which resulted in decreased metabolic acidosis (pH, 7.49; pCO₂, 30 mmHg; pO₂, 111 mmHg; bicarbonate, 22.9 mmol/L; total CO₂, 23.8 mmol/L; SaO₂, 99% on ABGA). Figure 2 shows change in vital signs after admission. Figure 3 shows changes in metabolic acidosis and after admission.

Table 1 shows the results of the tests performed during hospitalization. The patient did not undergo any further hemodialysis after admission. Metformin was discontinued, glimepiride was increased, and the patient was discharged after 6 days of hospitalization.

Discussion

Metformin is the most commonly used oral hypoglycemic agent in diabetes¹. However, when used in patients with renal impairment or other comorbid conditions, metformin may cause lactic acidosis, which can be a life-threatening condition².

The mechanism of MALA is complex. Metformin promotes the conversion of glucose to lactate in the splanchnic bed of the small intestine³. Metformin also inhibits mitochondrial respiratory chain complex 1, leading to decreased hepatic gluconeogenesis from lactate, pyruvate,

and alanine. This results in additional lactate and substrate for lactate production^{6,7}.

It is not easy to distinguish between blindness related to MALA and blindness related to other causes. In pre-

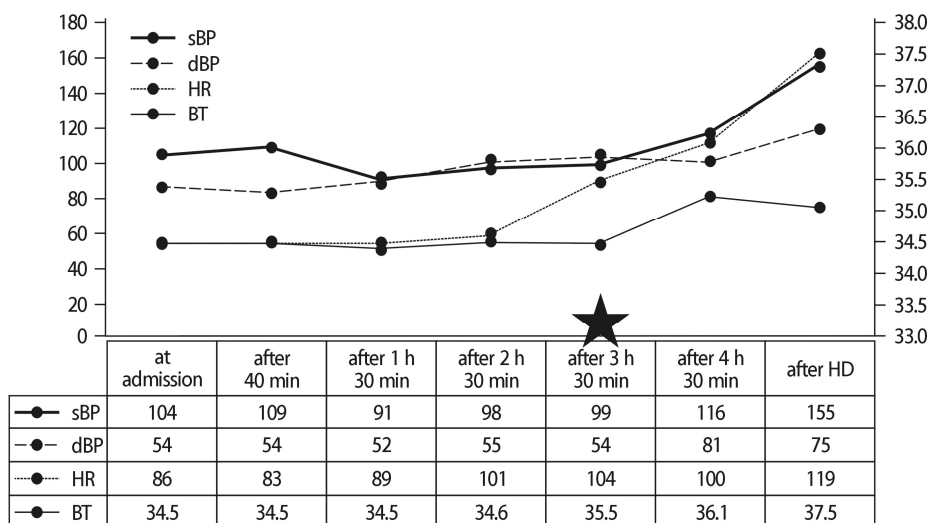


Fig. 2. Changes in patient vital signs. *sBP, systolic blood pressure; dBP, diastolic blood pressure; HR, heart rate; BT, body temperature. *★: vision recovery (3 h 30 min after admission).

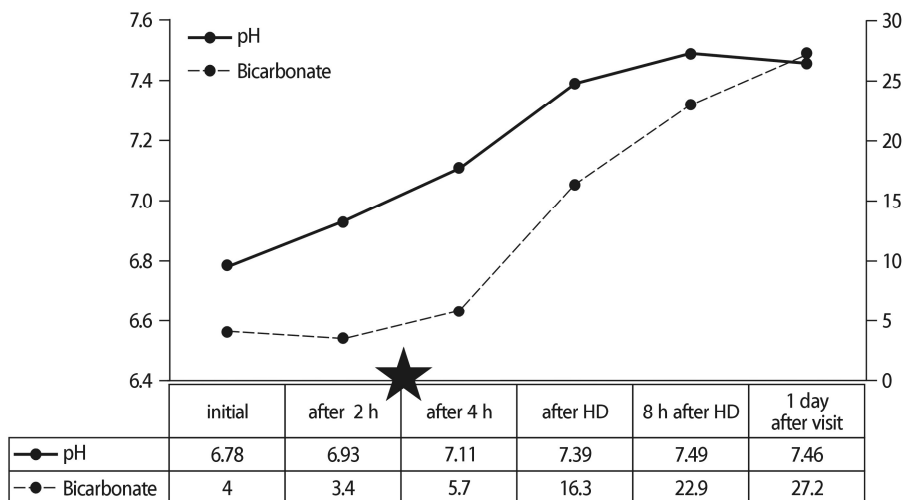


Fig. 3. Changes in metabolic acidosis. *★: vision recovery (3 h 30 min after admission).

Table 1. Laboratory values during patient hospitalization

| Laboratory parameter | On admission | Pre-HD | Post-HD | 3 day post-HD | 5 day post-HD |
|--------------------------------|--------------|--------|---------|---------------|---------------|
| pH | 6.78 | 7.11 | 7.49 | | |
| Bicarbonate (mmol/L) | 4.0 | 5.7 | 22.9 | | |
| Total CO ₂ (mmol/L) | 4 | 6 | 23.8 | | |
| Urea (mg/dL) | 36.9 | | 29.2 | 20.9 | 20.8 |
| Creatinine (mg/dL) | 2.31 | | 1.25 | 0.95 | 1.01 |
| Lactic acid (mmol/L) | >11 | | | 1.7 | |

Table 2. Literature review and patient characteristics, initial BP, and laboratory data

| | Cicarran S, et al. ⁹⁾ | Colin F, et al. ¹¹⁾ | Kreshak A, et al. ¹²⁾ | Our case |
|--------------------------------|----------------------------------|--------------------------------|----------------------------------|----------|
| Age/Sex | 54/Male | 49/Female | 67/Female | 68/Male |
| Initial BP (mmHg) | 70/52 | 130/70 | 117/94 | 104/57 |
| Initial BT (°C) | 36.8 | 37.0 | 32.3 | 34.3 |
| pH | 6.96 | 6.79 | 6.65 | 6.78 |
| Bicarbonate (mmol/L) | 3 | | <5 | 4 |
| Total CO ₂ (mmol/L) | | 5 | | 4 |
| Lactic acidosis (mmol/L) | 15.07 | 10 | 19.9 | >11 |

*BP, blood pressure; BT, body temperature.

vious cases, reversible blindness due to lactic acidosis was reported in diabetic patients^{8,9)}; a case of transient blindness due to diabetic ketoacidosis (DKA) and due to alcoholic ketoacidosis have also been reported^{10,11)}. The common features of these cases were severe metabolic acidosis with pH <7.0 and bicarbonate <5.0 mmol/L, and restoration of visual acuity after metabolic acidosis was corrected (Table 2). Therefore, in cases of sudden blindness in patients with severe metabolic acidosis, rapid correction of metabolic acidosis through hemodialysis may be helpful in differentiating this form of blindness from blindness related to other causes.

Transient blindness due to MALA is very rare and related risk factors are difficult to assess. Patients with severe metabolic acidosis (pH <7.0 and bicarbonate <5 mmol/L) in previously reported cases were compared. Hypothermia was present in our case and in another case, and hypotension was present in some cases (Table 2). Further investigation of associated risk factors is needed.

Our patient, unlike the previously reported MALA case, recovered his vision before metabolic acidosis was corrected with dialysis (pH, 7.11; pCO₂, 18 mmHg; pO₂, 77 mmHg; bicarbonate, 5.7 mmol/L; total CO₂, 6 mmol/L; SaO₂, 93% on ABGA) (Fig. 3). However, in a case of an alcoholic ketoacidosis patient, visual acuity was restored after hydration and intravenous sodium bicarbonate replacement¹¹⁾. This observation notwithstanding, in this case report, the degree of correction of metabolic acidosis was not reported.

In the present case, loss of vision could have resulted from two factors: hypotension and superimposed metabolic acidosis. According to previously published reports,

vision loss associated with MALA improved after correction of metabolic acidosis¹⁰⁻¹²⁾. The reported cases also showed the same pattern as our case with pH <7.0. Based on animal studies, the suggested mechanism involves the following: retinal cell function may be pH-dependent; retinal horizontal cell response to light is pH-sensitive; and mammalian retinal cell function becomes disrupted at pH <7.09). These effects could extend to humans and may serve as an explanation for acidosis-associated vision loss and optic nerve ischemia¹³⁾.

Conclusion

MALA is a common metformin-related adverse reaction. However, blindness associated with MALA has not been reported frequently. If blindness is accompanied by severe metabolic acidosis (pH <7.0, bicarbonate <5 mmol/L) associated with MALA, and if the cause of blindness is not clear, physicians should consider correcting metabolic acidosis through early hemodialysis. This approach could help distinguish blindness related to MALA from blindness related to other causes, and prevent retinal ischemia¹³⁾.

References

- American Diabetes Association. 8. Pharmacologic approaches to glycemic treatment: Standards of medical care in diabetes-2018. *Diabetes Care* 41(Suppl 1):S73-S85, 2018
- IRF. an Berlo-van de Laar, CG Vermeij, CJ Doorenbos: Metformin associated lactic acidosis: incidence and clinical correlation with metformin serum concentration mea-

- surements. *Journal of Clinical Pharmacy and Therapeutics* 36:376-382, 2011
3. Salpeter SR, Greyber E, Pasternak GA, et al.: Risk of fatal and nonfatal lactic acidosis with metformin use in type 2 diabetes mellitus. *Cochrane Database Syst Rev* 14(4), 2010
 4. Lalau JD, Andrejak M, Morinier P, et al.: Hemodialysis in the treatment of lactic acidosis in diabetics treated by metformin: a study of metformin elimination. *Int J Clin Pharmacol Ther Toxicol* 27(6):285-288, 1989
 5. Bailey CJ, Wilcock C, Day C: Effect of metformin on glucose metabolism in the splanchnic bed. *Br J Pharmacol* 105(4):1009, 1992
 6. Vecchio S, Giampreti A, Petrolini VM, et al.: Metformin accumulation: lactic acidosis and high plasmatic metformin levels in a retrospective case series of 66 patients on chronic therapy. *Clin Toxicol (Phila)* 52(2):129, 2014
 7. Sirtori CR, Pasik C: Re-evaluation of a biguanide, metformin: mechanism of action and tolerability. *Pharmacol Res* 30(3):187, 1994
 8. Sprensen PN: Transitory blindness during ethanol and phenethylbiguanide induced lactic acidosis in a subject with diabetes mellitus. A case report. *Acta Ophthalmol (Copenh)* 55(2):177-182, 1977
 9. Cicarran S, Rodriquez ML, Pousa M, et al.: Transient vision loss in a patient with severe metformin-associated lactic acidosis. *Q J Med* 105(8):781-783, 2012
 10. Deutsch G: Transient blindness associated with severe diabetic ketoacidosis. *Minn Med* 64(4):401, 1981
 11. Colin F, Marin M, Stephen B, et al.: Reversible blindness associated with alcoholic ketoacidosis: pseudomethanol intoxication. *J Emerg Med* 16(4):597-599, 1998
 12. Kreshak A, Clark R: Transient vision loss in a patient with metformin associated lactic acidosis. *Am J Emerg Med* 28:1059.e5-e7, 2010
 13. Osborne NN, Casson RJ, Wood JP, et al.: Retinal ischemia: mechanisms of damage and potential therapeutic strategies. *Prog Retin Eye Res* 23(1):91-147, 2004