

# Venetoclax with Azacitidine Induced Tumor Lysis Syndrome in an Elderly Patient with Acute Myeloid Leukemia: A Case Report

Mihee Kim<sup>1</sup>, Hyun-Jin Bang<sup>1</sup>, Ga-Young Song<sup>1</sup>, Seo-Yeon Ahn<sup>1</sup>, Sung-Hoon Jung<sup>1</sup>, Yong-Su Song<sup>2</sup>, Jae-Sook Ahn<sup>1,3\*</sup>

<sup>1</sup>Hematology-Oncology, Chonnam National University Hwasun Hospital, Jeollanam-do;

<sup>2</sup>Internal medicine, Chonnam National University, Gwangju;

<sup>3</sup>Genomic Research Center for Hematopoietic Diseases, Chonnam National University Hwasun Hospital, Jeollanam-do, Republic of Korea

Received: November 16, 2021

Revised: November 21, 2021

Accepted: November 22, 2021

Corresponding Author: Jae-Sook Ahn, MD, PhD  
Department of Hematology-Oncology, Chonnam National University Hwasun Hospital, 322 Seoyang-ro, Hwasun-eup, Hwasun-gun, Jeollanam-do 58128, Korea  
Tel: +82-61-379-7635; Fax: +82-61-379-8097  
E-mail: f0115@chonnam.ac.kr

Combination treatment with hypomethylating agents (HMAs) and venetoclax is being used increasingly in elderly patients with acute myeloid leukemia (AML). Venetoclax with HMAs has been reported to be associated with tumor lysis syndrome (TLS) in AML patients with high leukemic burden. We present a case of an elderly AML patient with low leukemic burden who developed TLS while receiving venetoclax and azacitidine (AZA). A 74-year-old man with newly diagnosed AML with NPM1 mutation received combination therapy with venetoclax and AZA in an outpatient clinic. Within 12 hours after starting venetoclax and AZA, the patient was admitted to the emergency room with fever, general weakness, and laboratory findings consistent with TLS. Based on our results, we recommend monitoring at the start of the treatment with venetoclax and HMAs to prevent and control TLS regardless of the leukemic burden and favorable genetic risk.

**Key Words:** Acute myeloid leukemia, Venetoclax, Azacitidine, Tumor lysis syndrome

This is an Open Access article distributed under the terms of the Creative Commons Attribution Non-Commercial License (<https://creativecommons.org/licenses/by-nc/4.0/>) which permits unrestricted non-commercial use, distribution, and reproduction in any medium, provided the original work is properly cited.

## INTRODUCTION

Combination treatment of hypomethylating agents (HMAs) and venetoclax is being used increasingly in elderly patients with acute myeloid leukemia (AML) who are unfit for intensive chemotherapy<sup>1-3</sup>. Venetoclax has been widely associated with tumor lysis syndrome (TLS) in patients with chronic lymphocytic leukemia (CLL). However, TLS after combination treatment with venetoclax and HMAs is rare in AML patients<sup>4-6</sup>. TLS is a potentially life-threatening complication following the administration of cytotoxic chemotherapy. It is caused by release of intracellular components into the bloodstream by rapid destruction of tumor cells, resulting in electrolyte and metabolic abnormalities<sup>7,8</sup>. We present a case of an elderly patient with AML who developed TLS

despite the low leukemic burden and favorable risk profile during treatment with venetoclax and azacitidine (AZA).

## CASE REPORT

A 74-year-old man with diabetes mellitus and hypertension presented with chronic fatigue. Initial complete blood count (CBC) revealed pancytopenia (white blood cell [WBC] count:  $1.5 \times 10^3/L$ , hemoglobin: 7.2 g/dL, and platelet count:  $104 \times 10^3/\mu L$ ). Lactate dehydrogenase (LDH) level was within the normal range (357 IU/L, normal: 218-472 IU/L). Laboratory findings of blood chemistry (potassium, calcium, phosphorus, and creatine kinase) were within the normal range (Table 1). Peripheral blood smear showed normocytic normochromic anemia with a left shift to myelocytes. A bone marrow biopsy was performed with the suspicion of a hem-

**Table 1. Laboratory findings related to tumor lysis syndrome according to the course of treatment**

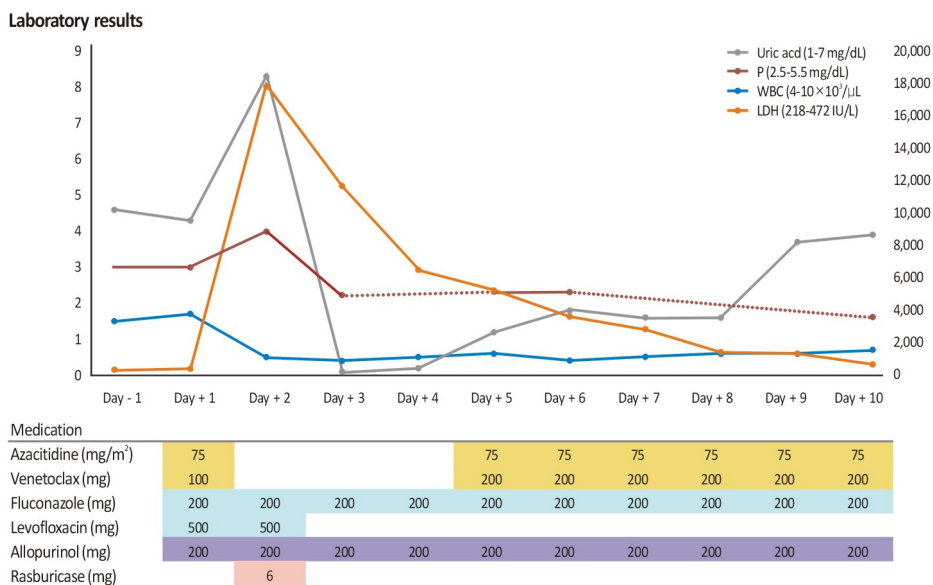
Laboratory Results (normal range)	Day -1	Day 1	Day 2	Day 3	Day 4	Day 5
WBC count ( $4-10 \times 10^3/\mu\text{L}$ )	1.5	1.7	0.5	0.4	0.5	0.6
Hemoglobin (12-18 g/dL)	7.2	8.4	8.6	7.2	9.1	11.1
Platelet count ( $130-450 \times 10^3/\mu\text{L}$ )	104	64	55	37	34	36
LDH (218-472 IU/L)	357	396	17,822	11,686	6,529	5,297
Uric acid (1-7 mg/dL)	4.6	4.3	8.3	0.1	0.2	1.2
BUN (8-23 mg/dL)	12.2	17.0	29.3	17.6	8.6	11.2
Creatinine (0.5-1.3 mg/dL)	0.62	0.84	0.86	0.79	0.59	0.75
Sodium (135-145 mEq/L)	135	133	136	137	140	138
Potassium (3.5-5 mEq/L)	3.8	3.8	3.5	3.1	3.3	3.8
Chloride (96-108 mEq/L)	94	92	97	100	103	99
Total calcium (8.4-10.2 mEq/L)	8.8	8.5	7.9			9.0
Ionized calcium (2.2-2.6 mEq/L)	2.22	2.14				
Inorganic phosphorous (2.5-5.5 mg/dL)	3.0	3.0	4.0	2.2		2.3
Magnesium (1.9-2.5 mg/dL)	1.75	1.86	2.04			2.02
Fibrinogen (180-350 mg/dL)	334		294	344	400	287
Innovance D-dimer (0-0.83 mg/L)	0.48		507.23	121.43	4.96	3.54
FDPs (0-5 $\mu\text{g/ml}$ )	2.70		>120	>120	16.97	11.23
Creatine kinase (32-187 U/L)	46		92			
Urine pH (5.0-8.0)	5.5		6.0	7.0		

Abbreviations: WBC, white blood cell; LDH, lactate dehydrogenase; BUN, blood urea nitrogen; FDPs, fibrin degradation products.

atologic malignancy or marrow failure syndrome. Initial bone marrow aspiration revealed 87.5% myeloblasts and hypercellular marrow for age (70% cellularity). The immunophenotype was compatible with AML with expression of CD33 (93.3%), CD117 (99.3%), and myeloperoxidase (98.7%).

The patient received combination therapy consisting of venetoclax 200 mg daily with a ramp-up dosing schedule (100 mg on day 1 and 200 mg on day 2, with subsequent continuation of the 200 mg/day) continuously for 28 days and  $75 \text{ mg/m}^2$  of AZA from day 1 to day 7 in cycle 1 (Fig. 1). Venetoclax was administered with concomitant fluconazole 200 mg and levofloxacin 500 mg for antifungal and antibacterial prophylaxis. Considering his good performance status and low disease burden (low WBC count and normal LDH level), the patient received chemotherapy in an outpatient clinic. He experienced fatigue and fever at 6 hours after starting venetoclax with AZA. Within 12 hours, the patient

was admitted to the emergency room with fever and general weakness. Blood tests showed hyperuricemia (8.3 mg/dL, normal: 1-7 mg/dL), marked elevation in the LDH level (17,822 IU/L), 25% increase of phosphorous (4.0 mg/dL) from baseline (3.0 mg/dL, normal: 2.5-5.5 mg/dL), and severe leukopenia ( $0.4 \times 10^3/\text{L}$ ). In urinalysis, urine pH showed 6.0 (5.0-8.0). The laboratory findings were consistent with the Cairo-Bishop criteria for the diagnosis of TLS (Table 1, Fig. 1)<sup>9</sup>. Rasburicase 6 mg and massive hydration with intravenous fluids were initiated for the treatment of TLS. AZA and venetoclax were stopped on days 2-4 and the first cycle of chemotherapy was restarted after resolution of TLS on day 5 (Fig. 1). CBC recovered at 32 days after starting the therapy (WBC count:  $7.9 \times 10^3/\text{L}$ , absolute neutrophil count:  $6.02 \times 10^3/\text{L}$ , hemoglobin level: 11.7 g/dL, and platelet count:  $335 \times 10^3/\mu\text{L}$ ). Follow-up bone marrow biopsy showed complete remission (CR) with a blast rate of 2.5% after the first



**Fig. 1. Dynamics in laboratory finding related to tumor lysis syndrome according to the course of treatment.**

Abbreviations: P, Inorganic phosphorous; WBC, white blood cell count; LDH, lactate dehydrogenase.

cycle of combination treatment with venetoclax and AZA. Initial cytogenetic analysis showed a normal karyotype, and next-generation sequencing revealed NPM1 mutations with 32.4% of variant allelic fractions without FLT3-ITD. The final diagnosis of the patient was AML with mutated NPM1, which has a favorable prognosis.

## DISCUSSION

Venetoclax with HMAs is a new standard treatment for older patients with AML<sup>10,11</sup>. Reportedly, venetoclax with HMAs improved the median overall survival from 9.6 to 14.1 months when compared with HMAs alone<sup>12</sup>. TLS occurrence is uncommon in AML during intensive induction chemotherapy (12% incidence of laboratory TLS and 5% of clinical TLS). Venetoclax has been widely associated with TLS in up to 13.4% of the cases of CLL<sup>13</sup>. However, venetoclax with HMAs showed a 2.5% incidence of laboratory TLS in AML and clinical TLS was rarely reported<sup>14,15</sup>. Despite the low incidence of TLS during combination treatment with venetoclax and HMAs in elderly AML patients, the National Comprehensive Cancer Network guidelines recommend a ramp-up dosing schedule of venetoclax to mitigate the risk of TLS. The guidelines also suggest prophylactic hydration,

administration of anti-hyperuricemic drugs before to the first dose of venetoclax, and monitoring of blood chemistry at 6-8 hours after each new dose ramp-up<sup>14</sup>. These recommendations were possibly due to the design of phase 1b trials, which had strict ramp-up dosing schedules for venetoclax and close monitoring for TLS considering its high prevalence in CLL<sup>16</sup>. Potential reasons for the higher incidence of TLS in CLL than that in AML may include differences in disease status. Venetoclax, a *BCL-2* inhibitor, has been used in refractory CLL patients and in patients who relapsed after B cell receptor pathway inhibitor treatment and showed rapid progression of the disease. TLS could be a consequence of the potency of venetoclax in inducing apoptosis of CLL cells<sup>17</sup>. A novel anti-leukemic effect was observed during combination treatment with venetoclax and HMAs in AML due to inhibition of anti-apoptosis as well as the potential to eliminate leukemic stem cells<sup>3</sup>. This finding may explain why TLS is rarely reported in association with combination treatment of venetoclax and HMAs when compared with intensive induction therapy in AML.

Although TLS is uncommon in AML<sup>1,16</sup>, there are a few reports of TLS in AML during treatment with venetoclax and HMAs<sup>4,5</sup>. We have reported a rare case of TLS induced by venetoclax and AZA treatment in an elderly AML patient

with low leukemic burden and favorable European Leukemia Net (ELN) risk profile. Previously reported cases included AML with intermediate to poor ELN risk profile, AML with mutated *ASXL1*, refractory AML with complex karyotype and mutated *ASXL1*, and AML secondary to myelodysplastic/myeloproliferative neoplasms<sup>4,5</sup>. Four out of six previous cases received strong CYP3A inhibitors for antifungal prophylaxis and could not achieve CR after combination treatment with venetoclax and HMAs<sup>4,5</sup>. A possible explanation for the risk of TLS in these cases was the patients' disease burden based on genetic profiling, peripheral circulating blasts, serum LDH level, and poor performance score. However, our patient had a favorable genomic profile (*NPM1* mutation) compared to other cases (*ASXL1*, *RUNX1*, and *TET2* mutations)<sup>5</sup>. Additionally, CR was achieved after the first cycle of treatment with venetoclax and AZA. We inferred that multiple factors such as comorbidities, performance score, disease burden, and baseline renal function could be the unexpected consequences of TLS in elderly AML patients.

Keruakous et al. reported that TLS was more prominent during treatment with strong/moderate CYP3A inhibitors for fungal prophylaxis at initiation and during the ramp-up phase of venetoclax, since concomitant use of venetoclax and strong or moderate CYP3A inhibitors increases venetoclax exposure<sup>4,12</sup>. Recent studies of drug-drug interaction between "azole" antifungal agents and venetoclax provided guidance for dose reduction of venetoclax in cases of concomitant use of antifungal agents<sup>14,18</sup>. However, most of these studies focused on strong CYP3A inhibitors such as posaconazole and voriconazole. Thus, information regarding the efficacy and drug interactions between moderate CYP3A inhibitors and venetoclax is insufficient. Compared to other cases of TLS, our patient received moderate CYP3A inhibitors (fluconazole 200 mg) and venetoclax was started at a dose of 100 mg with subsequent dose ramp-up. Further evaluation of appropriate venetoclax dose reduction when used with moderate CYP3A inhibitors is necessary to manage potential interactions with CYP3A inhibitors, reduce potential TLS complications, and ensure efficacy.

In conclusion, the present report describes a rare case of TLS after combination treatment with venetoclax and AZA in an elderly AML patient with favorable risk profile.

The patient had a low leukemic burden at the start of chemotherapy and was at a low risk of TLS (WBC count below  $25 \times 10^9/L$  and LDH level below twice the upper limit of normal). The time to TLS onset was within 12 h after receiving the first dose of venetoclax with AZA. Based on our results, we recommend close monitoring at the start of treatment with venetoclax and HMAs to prevent and manage TLS regardless of the leukemic burden at the start of chemotherapy.

### Disclosure of Competing of Interest

The authors declare no competing financial interests.

### REFERENCES

- DiNardo CD, Pratz K, Pullarkat V, et al. Venetoclax combined with decitabine or azacitidine in treatment-naïve, elderly patients with acute myeloid leukemia. *Blood*. 2019;133:7-17.
- Bogenberger JM, Kornblau SM, Pierceall WE, et al. BCL-2 family proteins as 5-Azacytidine-sensitizing targets and determinants of response in myeloid malignancies. *Leukemia*. 2014;28:1657-1665.
- Pollyea DA, Amaya M, Strati P, Konopleva MY. Venetoclax for AML: changing the treatment paradigm. *Blood Adv*. 2019; 3:4326-4335.
- Keruakous A, Saleem R, Asch AS. Venetoclax-induced tumor lysis syndrome in acute myeloid leukemia: Real world experience. *Journal of Clinical Oncology*. 2020;38(15\_suppl): e19542-e19542.
- Esparza S, Muluneh B, Galeotti J, et al. Venetoclax-induced tumour lysis syndrome in acute myeloid leukaemia. *British Journal of Haematology*. 2020;188:173-177.
- Roeker LE, Fox CP, Eyre TA, et al. Tumor Lysis, Adverse Events, and Dose Adjustments in 297 Venetoclax-Treated CLL Patients in Routine Clinical Practice. *Clin Cancer Res*. 2019;25:4264-4270.
- Hochberg J, Cairo MS. Tumor lysis syndrome: current perspective. *Haematologica*. 2008;93:9-13.
- Williams SM, Killeen AA. Tumor Lysis Syndrome. *Arch Pathol Lab Med*. 2019;143:386-393.
- Cairo MS, Bishop M. Tumour lysis syndrome: new therapeutic strategies and classification. *Br J Haematol*. 2004; 127:3-11.
- Maiti A, Qiao W, Sasaki K, et al. Venetoclax with decitabine vs intensive chemotherapy in acute myeloid leukemia: A

- propensity score matched analysis stratified by risk of treatment-related mortality. *Am J Hematol.* 2021;96:282-291.
11. Sekeres MA, Guyatt G, Abel G, et al. American Society of Hematology 2020 guidelines for treating newly diagnosed acute myeloid leukemia in older adults. *Blood Advances.* 2020;4:3528-3549.
  12. DiNardo CD, Jonas BA, Pullarkat V, et al. Azacitidine and Venetoclax in Previously Untreated Acute Myeloid Leukemia. *New England Journal of Medicine.* 2020;383:617-629.
  13. Rogers KA, Emond B, Manceur AM, et al. Real-world treatment sequencing and healthcare costs among CLL/SLL patients treated with venetoclax. *Current Medical Research and Opinion.* 2021;37:1409-1420.
  14. Jonas BA, Pollyea DA. How we use venetoclax with hypomethylating agents for the treatment of newly diagnosed patients with acute myeloid leukemia. *Leukemia.* 2019;33:2795-2804.
  15. Pelcovits A, Moore J, Bakow B, et al. Tumor lysis syndrome risk in outpatient versus inpatient administration of venetoclax and hypomethylators for acute myeloid leukemia. *Support Care Cancer.* 2021;29:5323-5327.
  16. DiNardo CD, Pratz KW, Letai A, et al. Safety and preliminary efficacy of venetoclax with decitabine or azacitidine in elderly patients with previously untreated acute myeloid leukaemia: a non-randomised, open-label, phase 1b study. *Lancet Oncol.* 2018;19:216-228.
  17. Roberts AW, Davids MS, Pagel JM, et al. Targeting BCL2 with Venetoclax in Relapsed Chronic Lymphocytic Leukemia. *New England Journal of Medicine.* 2015;374:311-322.
  18. Agarwal SK, DiNardo CD, Potluri J, et al. Management of Venetoclax-Posaconazole Interaction in Acute Myeloid Leukemia Patients: Evaluation of Dose Adjustments. *Clin Ther.* 2017;39:359-367.